



IPS e.max Press to Refractory to Achieve Conservative Excellence in Our Industry

Brad Jones, FAACD
Brent Engelberg, DDS

E sthetic dentistry strives to provide the ultimate in conservative, minimal prep, prepless or prep “less” veneers that are incredibly strong and absolutely beautiful. These criteria we have not previously been able to accomplish simultaneously. However, in select cases, which are carefully planned prior to preparation - utilizing lithium disilicate, pressed to refractory models, cutback, layered, then ideally bonded to enamel, it is possible today.

And if you thought e.max was beautiful at normal thicknesses of .5mm to 2mm, you should see what it looks like at .3mm and thinner. The author, Brad Jones, FAACD has been pressing to refractory exclusively for over a year now.

He finds that every tooth has its own set of circumstances and deserves its own consideration whether it can be “prepless” or prep “less”.

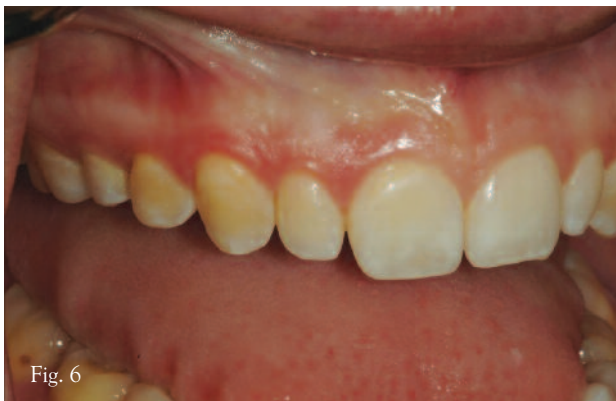
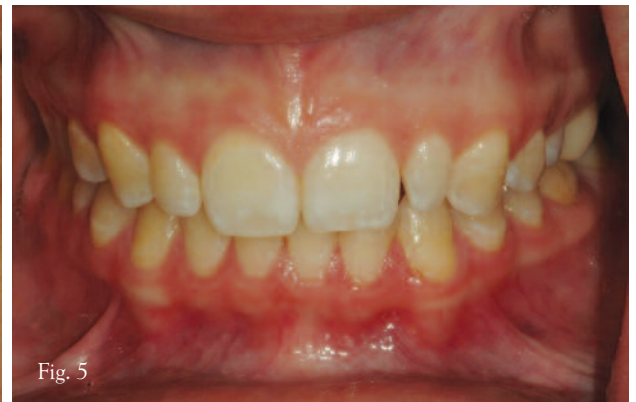
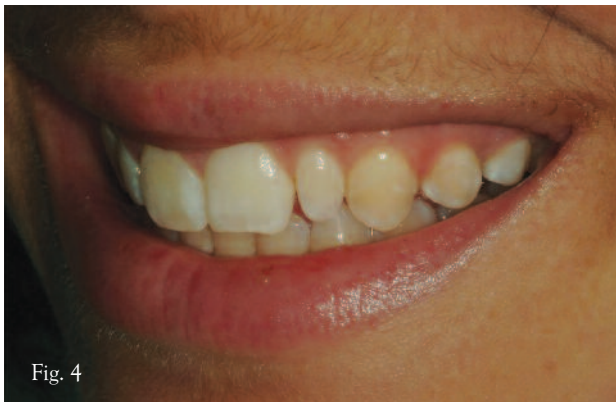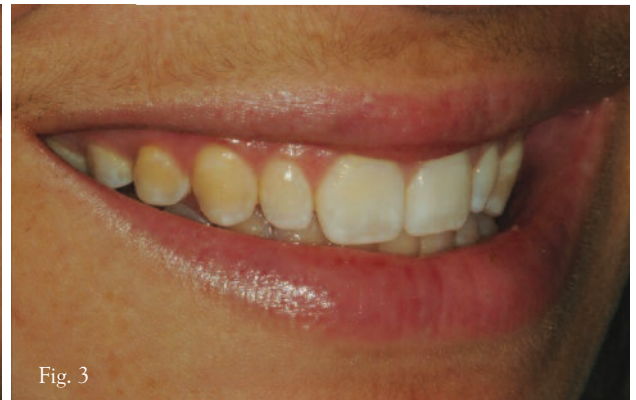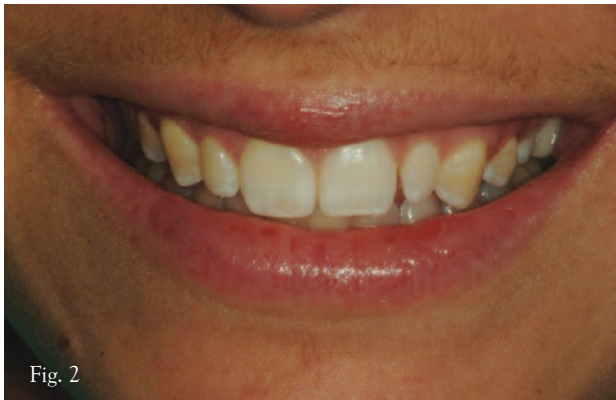Fig.1: Patient's pre-op portrait

Fig.2: Patient's pre-op natural smile

Fig.3: Patient's pre-op right lateral smile

Fig.4: Patient's pre-op left lateral smile

Fig.5: Patient's pre-op retracted

Fig.6: Patient's pre-op retracted right lateral

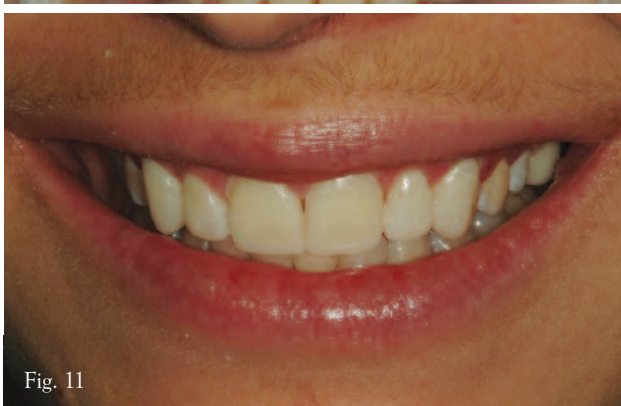
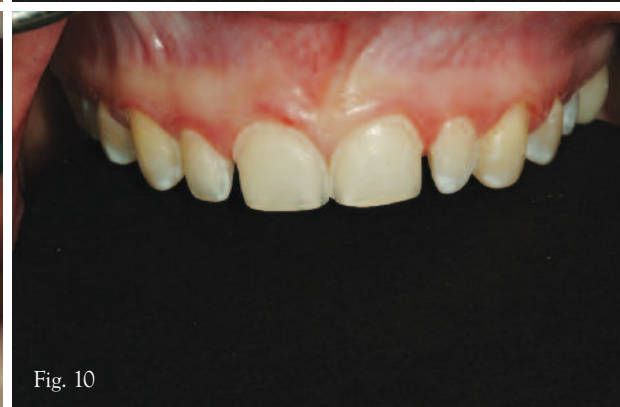
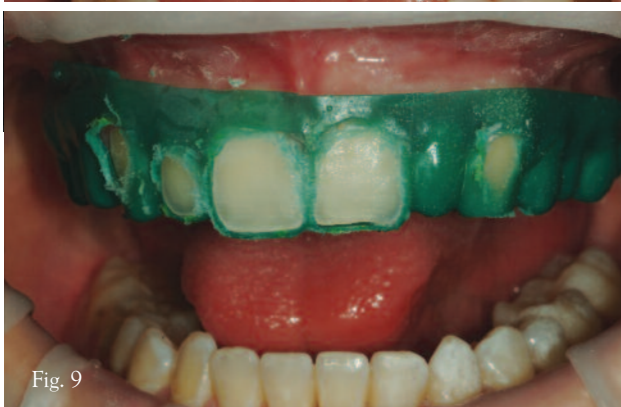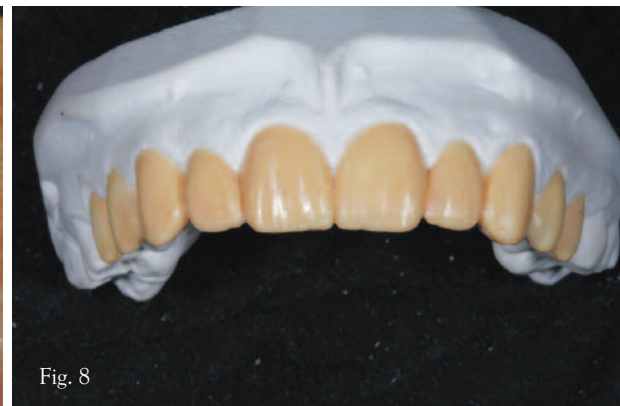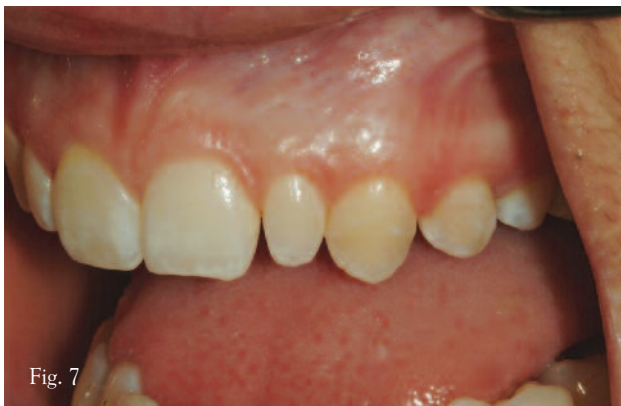Fig.7: Patient's pre-op retracted left lateral

Fig.8: Patient's diagnostic wax-up used for mock-up and provisional

Fig.9: Reduction stent for accurate minimal prepping

Fig.10: Patient's .3mm minimal preparations

Fig.11: Patient's natural smile with provisionals

The author finds that this conservative approach is not only cutting-edge, ultra-conservative dentistry, but by using a material that is both structural and esthetic, IPS e.max, bonded to enamel, it is the best our industry has to offer.

Case Study

This 20 year old female patient desired veneers that would make her upper teeth look more uniform or harmonious in height /width while making the tooth color brighter. One of the main goals of the patient was to make her larger central incisors appear narrower, while making her narrow lateral incisors appear larger and more symmetrical. In addition, the maxillary left canine cusp tip was noticeably lower than the maxillary right canine

(Figs.1-7). The clinician and the ceramist elected to take the most conservative and least invasive approach possible to achieve the desired results.

Pre-Clinical

A pre-op cast was poured and a green suck down material (L.A.K. Enterprise) was formed in a vacuum former over the cast. It was necessary to remove any tooth structure that lay outside of the arch form. This tooth structure was removed through this suck down stent material on the pre-op model. This reduction stent gives the clinician a quick head start in the initial reduction that is necessary before making the minimal .3mm depth cuts that were performed.

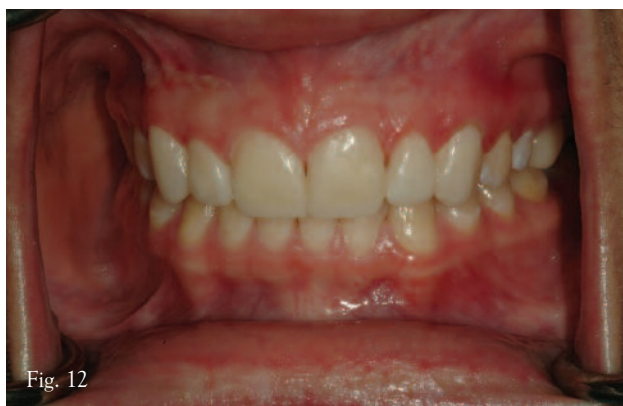

Fig. 12



Fig. 13

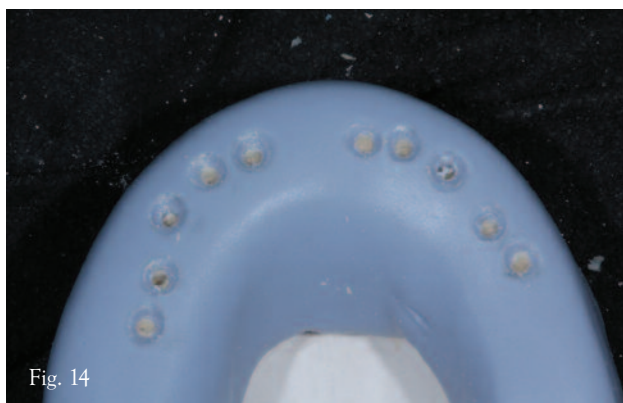

Fig. 14



Fig. 15

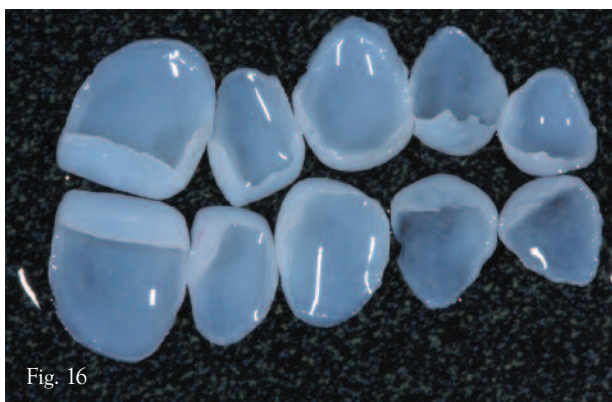

Fig. 16

Fig.12: Patient's retracted photo of the provisionals

Fig.13: The coveted photo, patient smiling eyebrow to chin

Fig.14: Matrix made from model of the provisionals used to wax-inject onto master model

Fig.15: IPS e.max Opal 2, ultra thin pressed cores

Fig.16: Pressed and fitted core ultra thin restorations

Clinical

The patient was anesthetized with 2 carpules of Septocaine (Septodont). The green laboratory-fabricated reduction stent was placed on the teeth and fully seated. With this initial reduction stent guide, the doctor can efficiently remove superfluous tooth structure that is outside the proposed arch form. Without this stent, the authors feel the amount of reduction will most certainly be greater than needed and will result in much less conservative preparations. In addition, time and thought can be saved because the stent always guides the preparations to their most accurate location.

Once the initial reduction was established, the preparation finish lines were established on teeth

6-11. Using a diode laser (Ivoclar, Vivadent), the gingival margin on tooth #11 was raised to create symmetry with the contralateral canine. The distal surfaces on the central incisors were lightly polished away in order to create room for adding to the mesial surfaces of the lateral incisors. Teeth 4, 5, 12, and 13 were not prepared at all because of their starting positions relative to the final position of the restorations. All preparations were done with Komet diamond burs and the polishing with Sof-Flex discs (3M ESPE).

A final impression (Imprint 3, 3M ESPE) was made and the provisionals were made using a Sil-Tech matrix (Ivoclar Vivadent) which was vacuum pressed to the additive-reductive wax-up. The patient was instructed to return in one week to

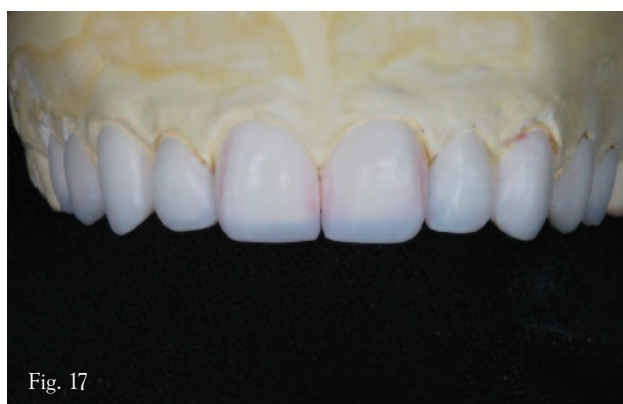

Fig. 17

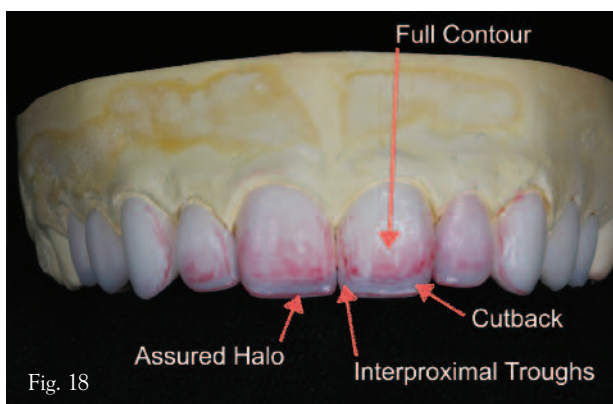


Fig. 18

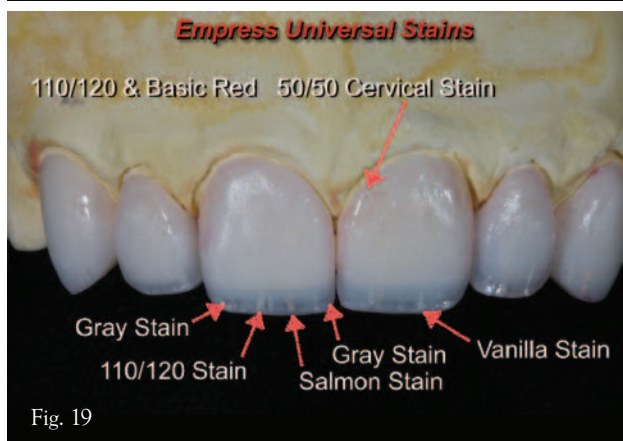

Fig. 19

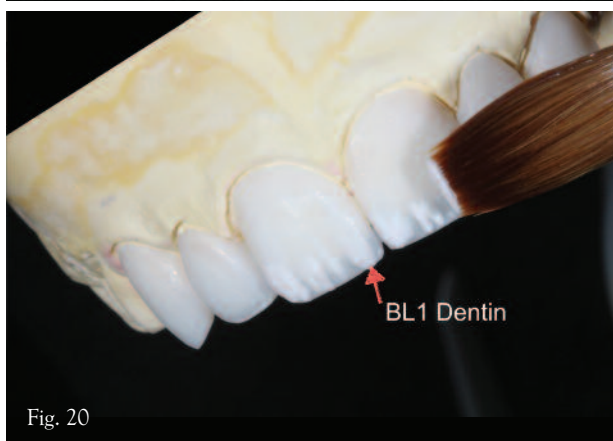


Fig. 20

Fig.17: Full contoured, fitted IPS e.max Opal 2 Cores ready for cutback and layering

Fig.18: Cutback ensures halo and natural low value incisal mesio-distal embrasures

Fig.19: Empress Universal Stains placed internally establish high and low value elements and emulate what is found deep inside the incisal edge and cervical areas of a natural tooth

Fig.20: After the internal stains were fired, BL1 dentin lobes were placed and feathered to mimic what is found in a natural tooth

verify that the esthetics of the provisionals was indeed correct.

Laboratory

The restorations were going to be .3mm thick or thinner and needed to be pressed to refractory. In order to filter out some of the light yellow-orange prep discoloration, the ceramist chose IPS e.max Opal 2 ingot material which would give the harmony of the patient's chroma with enhanced value to the patient's pre-op centrals and laterals.

After the approved provisional cast was poured up and a Sil-Tech (Ivoclar) matrix was formed, it was quickly placed into a pressure chamber at 60psi so that the Sil-Tech matrix would record not only the exact incisal edge position but all the incisal and gingival embrasures as well.

The thinness of these restorations (.3mm) made it

necessary to make an access hole to inject the Yeti Tho Wax to form each restoration. After the lost wax process was performed, the pressed lithium disilicate units were micro blasted with glass beads to remove the investment (Fig. 15).

Once the micro-thin veneer's sprues were removed and they were fitted to the master model-work (Fig. 17), you could see how much they would filter, to make the final restorations harmonious in the mouth (Fig.16).

Incisal Edge Cutback

In order to mimic the internal effects found in natural teeth, it was necessary to carefully perform a cutback for placement of the internal effects (Fig.18).

Internal Stain Effects

These internal effects started out with high and low

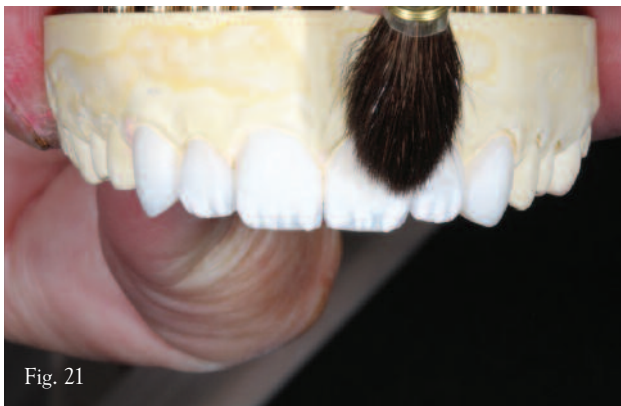

Fig. 21

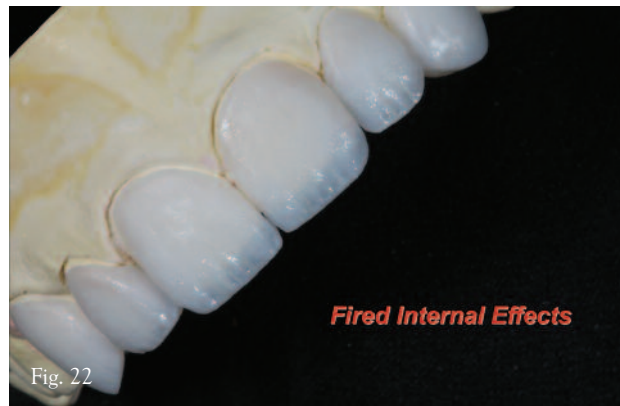

Fig. 22

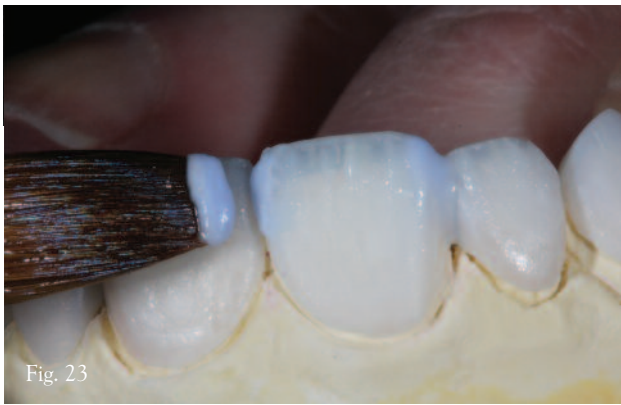

Fig. 23

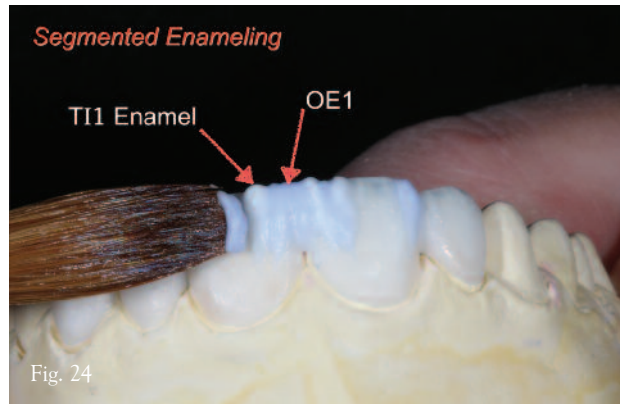


Fig. 24

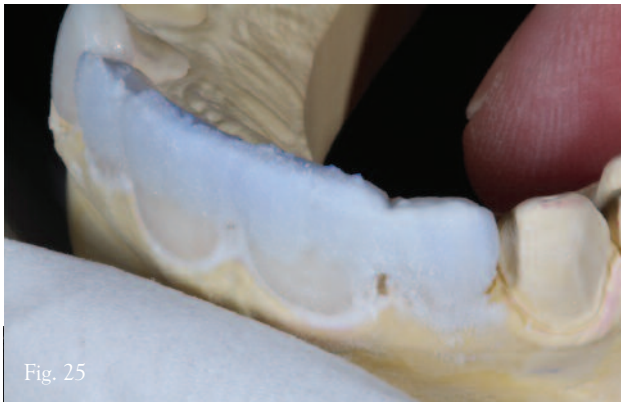

Fig. 25

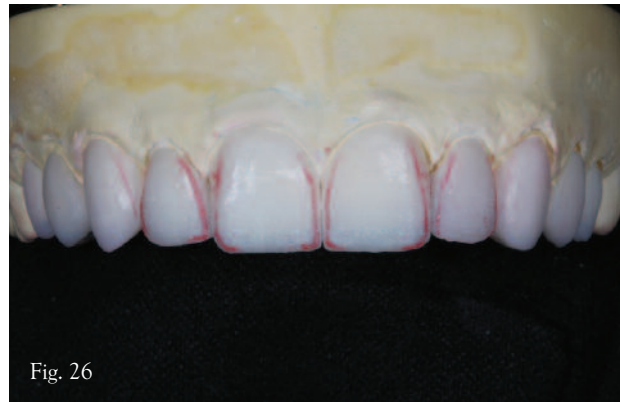

Fig. 26

Fig.21: Once the internal powder effects have been placed, it was necessary to dry brush away any loose porcelain powders from the full contoured (uncutback) areas

Fig.22: Fired internal effects

Fig.23: Opal Effects 1 (clear opal) was then placed in the incisal mesio-distal troughs to full contour

Fig.24: To finish the full contour enamels, Opal 1 and TI1 were segmented across the incisal one-third

Fig.25: Using a tissue these enamel powders were carefully rubbed back and forth to final shape and contour

Fig.26: Using a red pencil the desired line angles were marked so that all the important interproximals could be established

value stains (Ivoclar's Empress Universal Stains (Fig.19). These stains were fired at a high temperature of 730 degrees Celsius.

Internal Powders Effects

The second parts of the internal effects were

powders, Ivoclar's BL1 dentin and a 50/50 mixture of BL1/Salmon MM. They were placed to mimic the internal mesial, middle and distal mamellons of a natural tooth (Fig.20). It was necessary to blend these powders both apically and incisally with a dry fluffy brush. All the powders that were placed outside the cutback areas were then removed

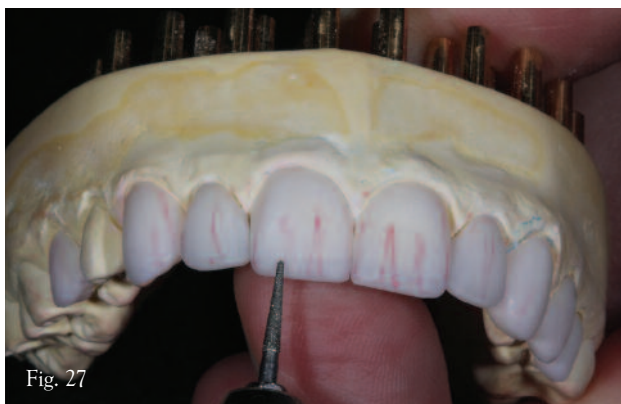

Fig. 27

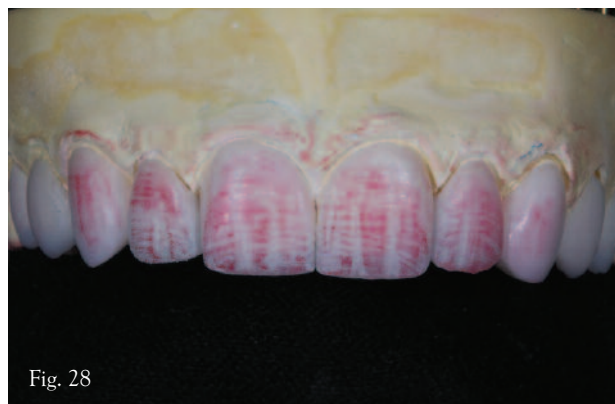

Fig. 28

Fig.27: Once the shape and contours were finalized the developmental grooves were marked using a red pencil and cut in with a needle point tapered diamond (Komet 000-00)

Fig.28: Final surface texturing was completed by using a rotary diamond instrument (Cardinal 0000-00) to put in the perykamata, mimicking the surface of a natural tooth

(Fig. 21). These effects were fired at a high temperature of 750 degrees Celsius under full vacuum and were evaluated (Fig. 22), prior to the final enameling.

Enameling the Incisal

The full contour enameling began with Opal Effect 1 (clear, opal, powder) which was placed in the mesial, distal, incisal, trough areas; a segment of Translucent Incisal 1 (high value incisal powder) was then placed alternating slices from mesial to distal clear opal troughs (Fig. 24). The ceramist was careful not to overbuild these enamel powders so that the final tooth form would not be lost. These powders were condensed using a tissue over the index finger until the perfect full contour incisal thickness was achieved (Fig. 25). An ultra-thin blade was used to cut and carve into the interproximal areas of these incisors until they became separated. Then the ceramist used his finger to carefully finish out the interproximal deflective zones of the individual raw porcelain units. They were fired at 750 degrees Celsius under full vacuum.

Final Shape and Contouring

After evaluating the final full contoured enamel bake, a red pencil was used to carefully lay out the mesial, distal line angles or heights of contours (Fig. 26); a pair of dividers were used to measure the width between the two red lines on tooth number 8 to number 9 and tooth number 7 to tooth number 10, until the ceramist was certain on the symmetry. These mesial and distal interproximal areas between the veneers are to deflect the light away from the eye

(deflective zones). These deflective zones were developed using a Blue Dia-Lite (Cardinal Rotary Instruments 6509-170-1) wheel. By using the flat cutting surface, the ceramist was able to mimic these most important deflective zones that make the restorations look naturally individual.

Surface Morphology

Using the red pencil, very tiny Eiffel Towers (developmental grooves) were carefully planned out between the mesial, middle and distal surface lobes (Fig. 27). Because of the thinness (.3mm) of these veneers, the ceramist chose to use a very fine tapered diamond (Cardinal Rotary Instruments) in a high speed hand piece to develop these surface grooves (Fig. 27).

Parakymata was then placed over the veneer surfaces to mimic nature using a spiral diamond burr (Cardinal Rotary Instruments T5856.104.023), being very careful not to fracture the restorations. Now that the surface morphology was completed, a red marking film was used to make sure it was the exact amount of surface detail prior to the glaze (Fig. 28).

The ceramist prefers the non-florescent e.max glaze paste and places approximately 1/3rd of the glaze syringe to one drop of the liquid medium into a little bottle and by using a flexible plastic spatula (art store) it is mixed and tested to be perfect before applying it (Fig. 29).

The glaze mixture is saturated over the layered and non-layered surfaces of the veneers by using a glaze

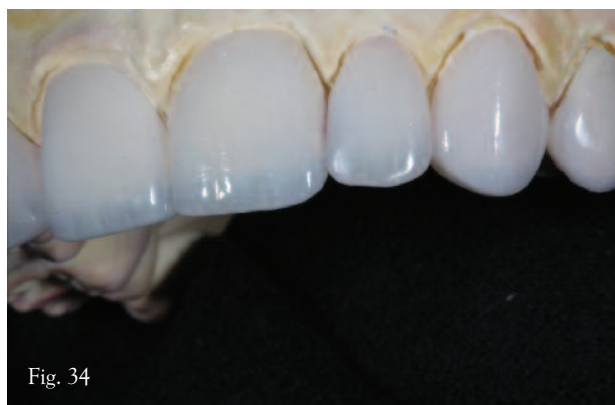
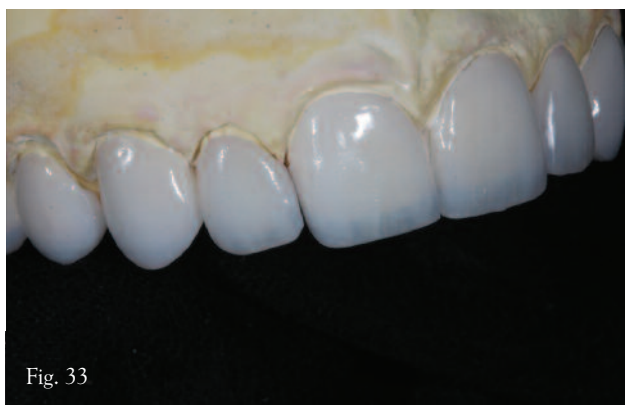
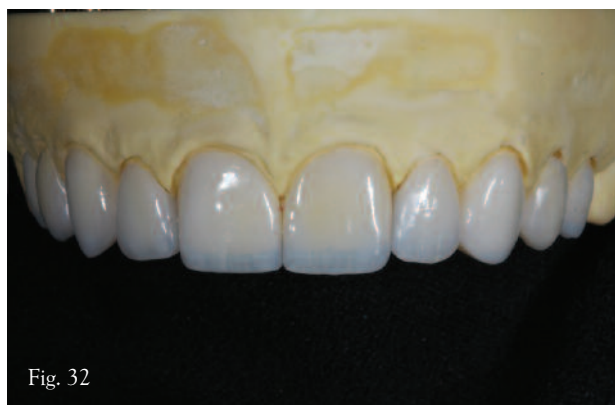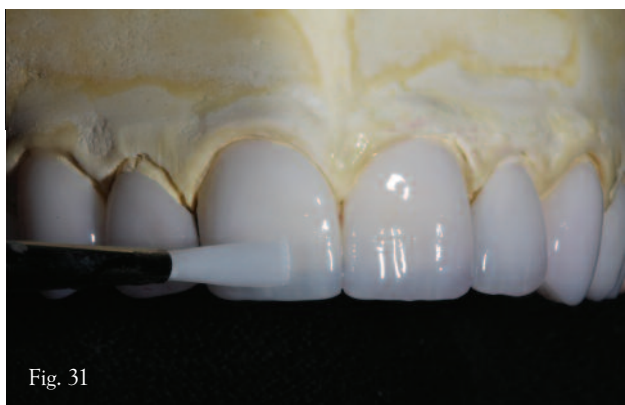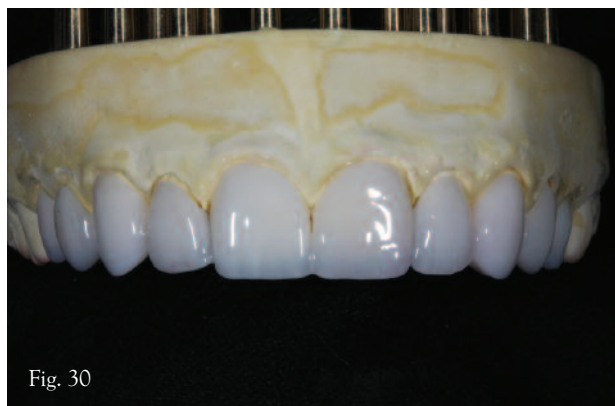Fig.29: E.max non-fluorescent glaze

Fig.30: Allow the heavy glaze to soak into the textured surface

Fig.31: Carefully remove excess glaze over layered portion of the restoration to promote a natural glaze in this area

Fig.32: This overall artificial glaze is ready to be knocked down using a soft knife edge rubber wheel

Fig.33: This final shine is brought in by a high polishing wheel to mimic the surface reflection of a natural tooth

Fig.34: The shine of a natural tooth is highly polished in some areas and less shiny in others; areas are mimicked in the restorations

brush to be soaked into the surface texture (Fig. 30). Then by using a white nylon round brush number 1 (Fig. 31), the excess is slightly removed from the layered portion only until you just start to see the surface detail.

Then the ceramist uses his little finger to remove

any glaze from the interproximal contacts, (the contacts will be polished after the glaze is fired).

Now the glaze is fired under full vacuum at a high temperature of 750 degrees Celsius with a rate of climb of 70 degrees per minute. Then, the high temperature is held without vacuum for a final 30 seconds before the muffle is opened to cool.

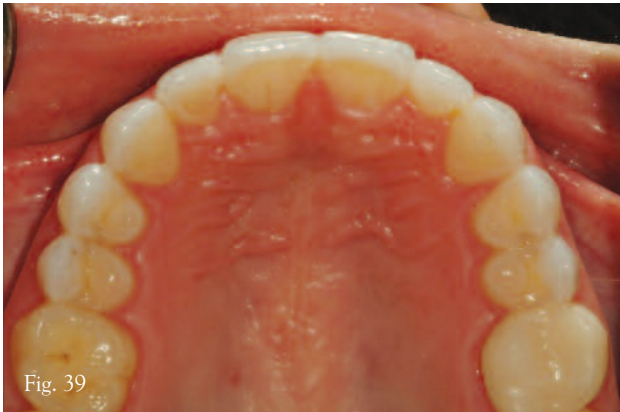
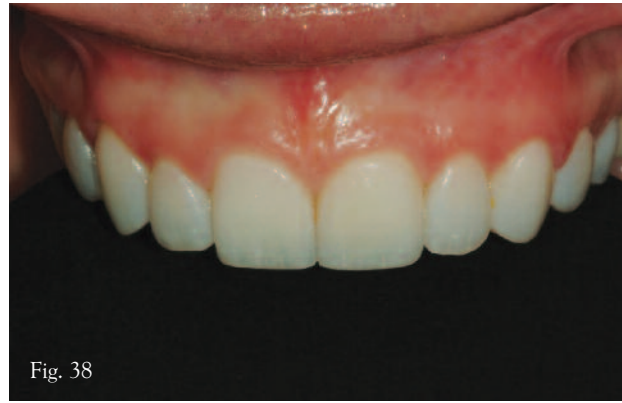
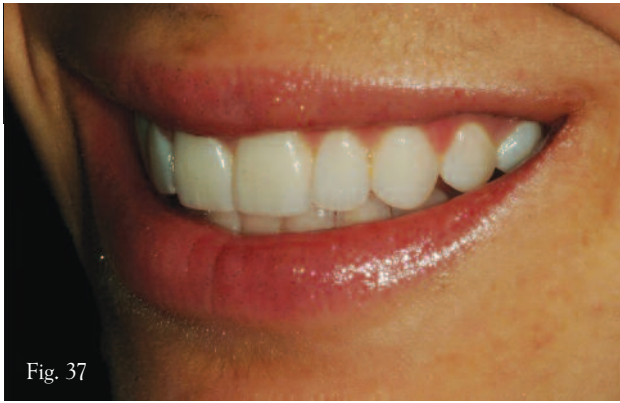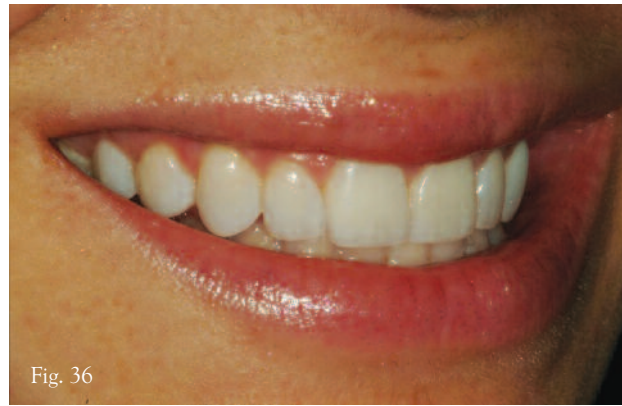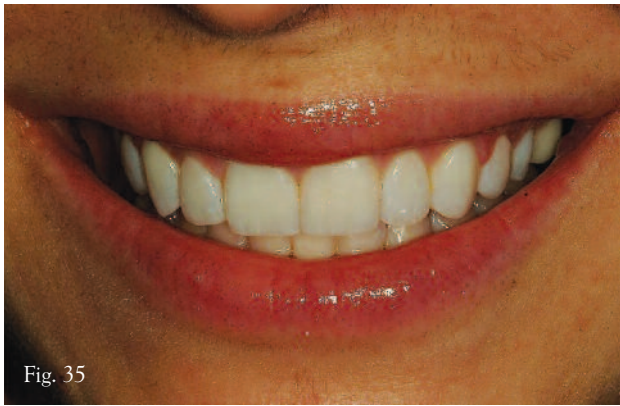Fig.35: Post-op smile with IPS e.max pressed to refractory final restorations

Fig.36: Right lateral post-op view of the patient's smile

Fig.37: Left lateral post-op view of the patient's smile

Fig.38: Retracted post-op view of final restorations

Fig.39: Post-op clinical full face view

The surface of natural dentition is neither all highly polished nor completely dull, it is both. Some areas are dull like in between the lobes and in the grooves. All glaze powders and pastes after being fired come out in a very brassy and artificial appearance and therefore it is necessary to take this artificial surface further.

A Komet knife-edge pink rubber wheel (Komet) is used to soften and dull the brassy artificial looking glazed surface, being careful not to take away the desired surface morphology. Having completed the mimicking of the surface found in the natural anterior teeth, it was necessary to bring up the high-shine gloss in certain areas. The ceramist used a

large peach colored Dia-lite knife-edge polishing wheel specially made for polishing e.max (Cardinal Rotary Instruments 6625-250-1) to mimic the surface of a natural tooth. This knife-edge wheel is used to polish the areas of the tooth, where in nature the lip is naturally polishing it (Figs. 32-34).

Evaluating the Final Restorations

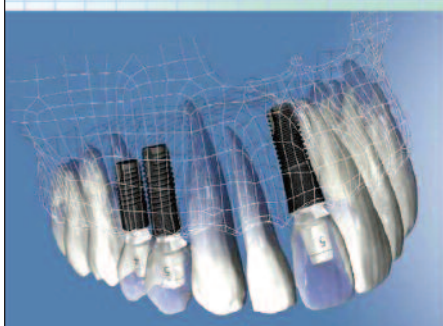
It really doesn't matter how beautiful these IPS e.max Opal 2 restorations look on the bench. What matters is what these veneers look like in our patient's smile (Figs. 35-37). Also, do they look undetectable intraorally? (Figs. 38 and 39).

STOMATOTECH

SGLA™

Surgical Guide Laser Aligner

**NEW
IN-LAB
SURGICAL GUIDE**



**Small INVESTMENT,
BIG RETURNS**

- Same day fabrication
- Laser technology
- 3-Dimensional
- Free Training
- Full support



CALL NOW 1-888-559-7795

**OR
VISIT ONLINE**

www.stomatotech.com



Fig. 40



Fig. 41

Figs.40 and 41: Post-op portrait of the patient with new smile

In Conclusion

Today's patients are coming in younger and younger, wanting to take advantage of a beautiful, powerful smile which will give them unbelievable confidence and will open doors of opportunities that might have otherwise been closed. It is most important that with today's

mad rush to the CAD/CAM's we don't forget about the artistry of what an individual master ceramist can achieve by emulating what nature has to teach us.

There is no better restorative material out there that proves to be both structural and most importantly esthetic. **SI**

About the authors



Brad Jones, FAACD, his passion is creating beautiful natural looking smiles. His vision in light and color enables him to create the inner life of a natural tooth. He goes beyond the elementary principals of smile design by maintaining some of the patient's natural elements. In doing so he is able to individualize each and every smile. Brad Jones is a Fellow member of the American Academy of Cosmetic Dentistry (AACD) making him one of only four ceramists in the world, eighty countries, to hold this honor. He is also an AACD accreditation examiner and recently served four years on the AACD Board of Directors. He is currently serving as a member of the AACD's Professional Education Committee (PEC), where he is working on the scientific educational programs designed to elevate the clinical skills of all dental professional attendees. He is an international lecturer, accomplished author and instructor on advanced dental ceramics. (www.whysmile.com)



Dr. Brent Engelberg earned his doctor of dental surgery degree from the Indiana University School of dentistry. He has committed himself to a career of continuing education on the most state-of-the-art functional and esthetic procedures and techniques and co-directs his multidisciplinary study club in the Chicago suburbs. His Arlington Heights, Illinois practice's focus is primarily on adult cosmetic and restorative dentistry (www.glamoursmiles.com). Dr. Engelberg enjoys lecturing and has published articles on cosmetic dentistry, full-mouth rehabilitation and porcelain veneer techniques. He is also a co-director of Total Advantage Live, and over-the-shoulder and hands-on course teaching cosmetic dentistry techniques from treatment planning and preparation through laboratory synergy and case completion to dentists (www.totaladvantagelive.com). He can be reached at (847)259-6988.